

# Correction of a Canine Left-to-Right Shunting

By Connie K. Varnhagen, PhD, RAHT

## Patent Ductus Arteriosus

Scrappy, a 5-year-old, 27-kg, neutered Labrador retriever, presented to the Calgary Animal Referral and Emergency (CARE) Centre in Calgary, Alberta, Canada, for mild exercise intolerance. The owner reported that the normally active dog was “slowing down” and panting excessively even after mild exercise.

### History

The patient was the runt of its litter, was rejected by its dam, and was hand-fed for the first 5 days. A presumed innocent heart murmur was detected on auscultation at the puppy's first veterinary examination.

At approximately 6 months of age, the patient began experiencing chronic small intestine diarrhea and weight loss. Over the next 30 months, the dog was diagnosed and treated for giardiasis, coccidiosis, small intestinal bacterial overgrowth, borderline exocrine pancreatic insufficiency, and lymphocytic plasmacytic inflammatory bowel disease.

Also at approximately 6 months of age, the patient developed a nonseasonal pruritus and dry, brittle haircoat. Atopy was diagnosed from punch biopsies.

At the time of presentation at the CARE Centre, the patient's chronic diarrhea was being well maintained on a hypoallergenic diet and the atopy was moderately maintained with cool baths with antipruritic shampoos and topical treatment of occasional skin infections.

### Evaluation

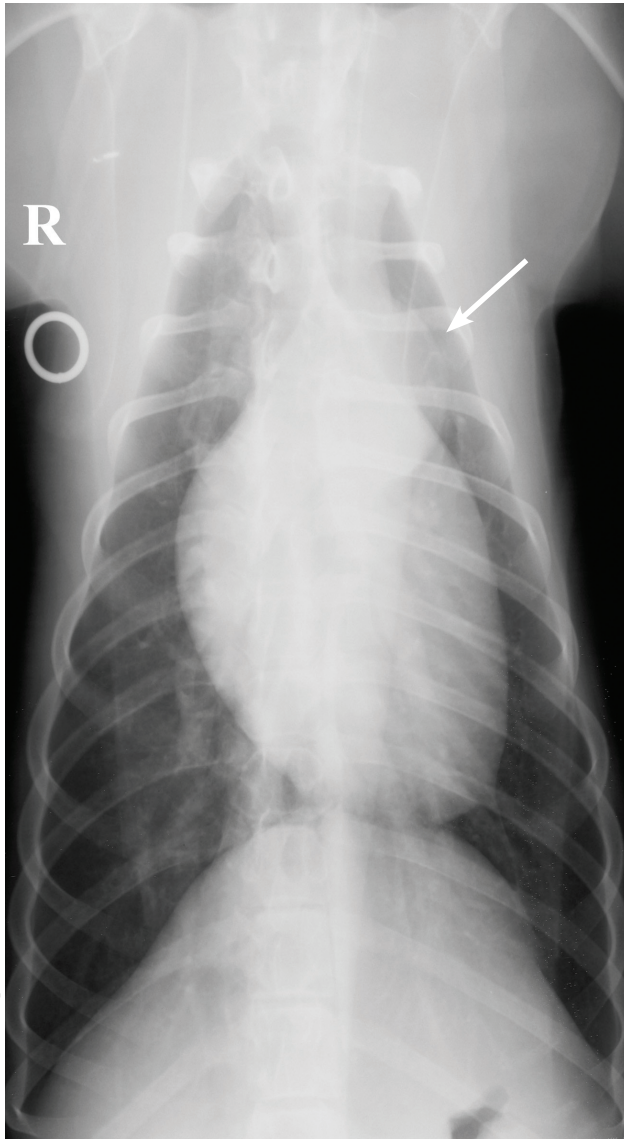
Physical examination revealed a precordial thrill, a grade V/VI continuous murmur with the point of maximal intensity over the left heart base and exuberant femoral and gingival membrane pulses. No heart arrhythmias were noted, heart rate was 60 bpm (normal: 70-120), and capillary refill

time and mucous membrane color were normal. Lung sounds were normal on auscultation. Based on the physical examination, the differential diagnosis included patent ductus arteriosus (PDA) or another type of arteriovenous fistula.

Right lateral and ventrodorsal (Figure 1) thoracic radiographs revealed cardiomegaly with left atrial and ventricular enlargement and a prominent pulmonary artery bulge. Electrocardiography (ECG; Figure 2) demonstrated a tall R wave (greater than 4.0 mV in lead II compared with a normal parameter of 3.0 mV), indicative of left ventricular enlargement, and normal sinus rhythm.

Echocardiography was performed and was definitive for a left-to-right shunting PDA (Figure 3). The diameter of the PDA at the pulmonary artery was 4.8 mm. Color Doppler also revealed mild to moderate mitral valve insufficiency with at least two jets. Trivial aortic, tricuspid, and pulmonic valve insufficiency were also apparent. M-mode measurements confirmed the ECG finding of an enlarged left ventricle (left ventricle internal diameter of 6.39 cm at diastole and 4.70 cm at systole compared with normal parameters of 4.2 cm at diastole and 2.8 cm at systole for a normal dog at the same weight<sup>1</sup>) and demonstrated moderately reduced left ventricle contractility. The left atrium and pulmonary artery also were moderately enlarged.

A complete blood count (CBC) revealed low normal RBCs (561/ $\mu$ l, reference range: 550-850), mild leukope-



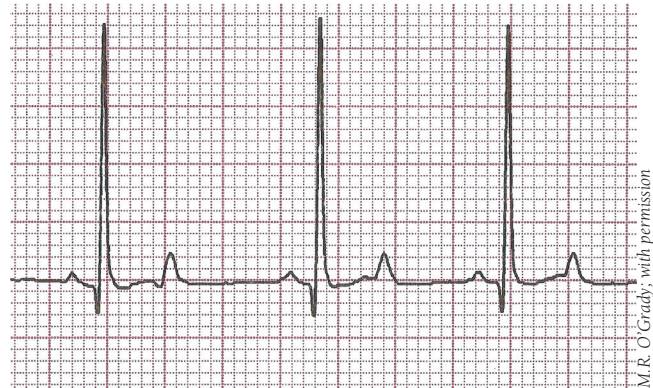
M.R. O'Grady, with permission

**Figure 1.** Ventrodorsal thoracic radiograph. The heart is enlarged, taking up five ribs (compared with a normal heart size of four ribs), with a large left atrium and ventricle and a large pulmonary artery bulge (arrow).

nia with marginally low numbers of lymphocytes (900/ $\mu$ l, reference range: 1200–4500) and monocytes (200/ $\mu$ l, reference range: 300–1000), low granulocytes (2600/ $\mu$ l, reference range: 3500–12,000), and marginally low numbers of platelets (196,000/ $\mu$ l, reference range: 200,000–500,000). A complete biochemistry profile revealed a marginally low total protein of 5.3 g/dL (reference range: 5.4–8.2), with a low globulin of 1.7 g/dL (reference range: 2.3–5.2). All other parameters were within normal limits.

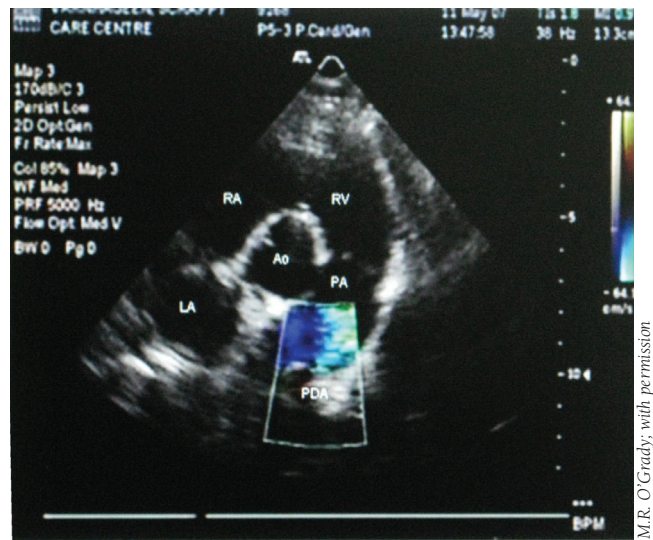
### Therapy

To promote arterial vasodilatation and reduce afterload on the left ventricle, enalapril maleate, 0.5 mg/kg BID, was



M.R. O'Grady, with permission

**Figure 2.** ECG tracing, Lead II (5 fine lines vertically = 1 mV; 25 fine lines horizontally = 1 second). Normal R-wave height should be 3.0 mV.



M.R. O'Grady, with permission

**Figure 3.** Color Doppler of PDA from transverse section through the heart base. The blue color represents flow through the pulmonary artery; the green color represents the PDA jet causing turbulent flow from the higher pressure aorta, through the ductus arteriosus, and into the lower pressure pulmonary artery. LA = left atrium, RV = right ventricle, RA = right atrium, PA = pulmonary artery, PDA = patent ductus arteriosus, AO = aorta.

prescribed. Occlusion of the PDA with an Amplatz canine duct occluder (ACDO) was advised (Figure 4).

The procedure was performed at the Ontario Veterinary College by M. Lynne O'Sullivan, DVM, DVSc, DACVIM (Cardiology), assistant professor of clinical studies, with Michael O'Grady, DVM, MSc, DACVIM, assisting.

Because of the PDA, the patient was assessed as an American Society of Anesthesiologists (ASA) Class III, Moderate risk.<sup>2</sup> Premedication consisted of 2 mg hydro-morphone HCL administered IM. Following preoxygenation, the patient was induced with propofol at 60 mg and diazepam at 6 mg, administered to effect. A 10-mm endotracheal tube was inserted and the patient was maintained

(text continues on page 36)

## Patent Ductus Arteriosus

Patent ductus arteriosus (PDA) is the most common congenital cardiac defect in dogs and is caused by an incomplete closure of the fetal ductus arteriosus. Female dogs are more commonly affected and a genetic link has been suggested in many breeds.<sup>3-6</sup>

The ductus arteriosus is an arterial shunt between the pulmonary artery and the aorta that allows fetal circulation to bypass the lungs. Resistance from the fluid-filled developing pulmonary vessels in the fetus prevents blood from flowing from the pulmonary artery into the lungs. Instead, the blood flows through the ductus arteriosus and into the aorta. With respiration following birth, pulmonary resistance drops and blood flows into the lungs instead of through the ductus arteriosus. Decreased maternal prostaglandins, coupled with endogenous vasoactive and prostaglandin-inhibiting substances, are thought to support vasoconstriction within the ductus arteriosus.<sup>7</sup> The ductus closes over during the first hours to days following birth.<sup>4-6</sup>

In PDA, the ductus arteriosus fails to close, remaining patent. Most commonly, circulation through the ductus arteriosus flows from the higher pressure aorta to the pulmonary artery (left-to-right shunting).<sup>4-6</sup> Less commonly, pulmonary hypertension leads to circulation from the pulmonary artery to the aorta (right-to-left shunting).<sup>4-6,8,9</sup> In left-to-right shunting PDA, a certain amount of blood recirculates through the pulmonary system and back through the left side of the heart. This results in volume overload in the pulmonary circulatory system and in the left atrium and ventricle. This in turn leads to increased pressure and hypertrophy of the affected structures.<sup>4-6</sup>

Left-to-right shunting PDA is categorized into four types, according to severity of the symptoms and clinical features:<sup>5,6</sup>

- ▶ **Type 1, small PDA:** the animal is asymptomatic and the PDA may be identified at a puppy wellness exam. A continuous murmur may be appreciated over the left heart base. No other findings are apparent.<sup>5,6</sup>
- ▶ **Type 2, medium PDA:** the animal is still generally asymptomatic. A continuous murmur is appreciated at the left base and apex and a precordial thrill can be felt at the left heart base. Peripheral pulses (particularly the femoral and gingival membrane pulses) may be hyperkinetic or bounding. Changes in the cardiac silhouette may be noted on radiograph, including left heart enlargement and arterial bulges. The R wave in the ECG may be slightly taller than normal. The Type 2 PDA will also be apparent in a color Doppler echocardiograph (Figure 3).<sup>5,6</sup> Blood flowing in a vessel toward the

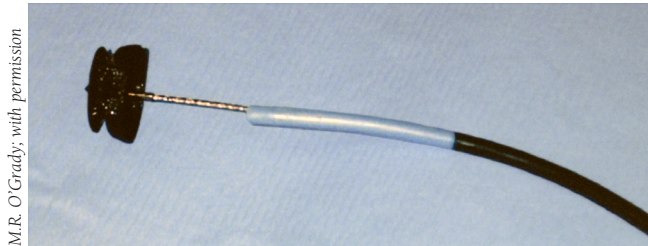
transducer will be red and blood flow away from the transducer will be blue. Thus, blood returning to the heart in the pulmonary artery will be one color and blood leaving the heart through the aorta will be another color. Blood flow across the PDA will be turbulent, with blood flowing in multiple directions. The resulting color Doppler image will be green.

- ▶ **Type 3A, large PDA:** the animal may present for reduced exercise tolerance. The continuous murmur and thrill are easily appreciated and a systolic murmur may be present due to mitral valve regurgitation. Pulses are exuberant and the gingival pulse is easily visualized. Radiographic changes include marked left-sided heart enlargement and a prominent aortic bulge (Figure 1). The R wave in the ECG is markedly high (Figure 2). The PDA is easily visualized in a color Doppler echocardiograph.<sup>5,6</sup>
- ▶ **Type 3B, large PDA with congestive heart failure:** the animal will have all the symptoms and clinical features of the Type 3A PDA, but also will present with dyspnea and poor body condition. Clinical findings of congestive heart failure may include pulmonary edema and atrial fibrillation.<sup>5,6</sup>

Surgery or occlusion is used to correct a left-to-right shunting PDA; without surgery, up to 65% of affected dogs die within the first year.<sup>10</sup> Surgery consists of a thoracotomy and ligation of the ductus arteriosus. Surgery is typically successful and has a low surgical mortality rate of 2%–8%.<sup>5,6,10</sup> Occlusion of the ductus arteriosus through transcatheter insertion of embolization coils is much less invasive than thoracic surgery and also has a low mortality rate.<sup>5</sup> Embolization coils do not completely occlude the PDA, however, and a number of cases have been reported in which the coils have migrated out of the ductus arteriosus.<sup>11</sup>

Recently, a human device to occlude vessels and heart structures has been used to occlude a PDA in a dog.<sup>12,13</sup> Based on initial success, a canine version was created that has two discs to block off the PDA from both the pulmonary artery and the ductus arteriosus sides of the PDA.<sup>14</sup> The Amplatzer canine duct occluder (ACDO) has been successfully placed in dogs ranging in weight from 3.8 kg to 32.3 kg with PDA types ranging from asymptomatic Type 1 to Type 3A/B associated with mild congestive heart failure.<sup>14</sup> The transcatheter insertion procedure for inserting the ACDO is only slightly more complicated than coil placement. Although the database of cases is small, there have been very few reports of device migration, and no reports of mortality associated with occlusion with the ACDO.<sup>14</sup>



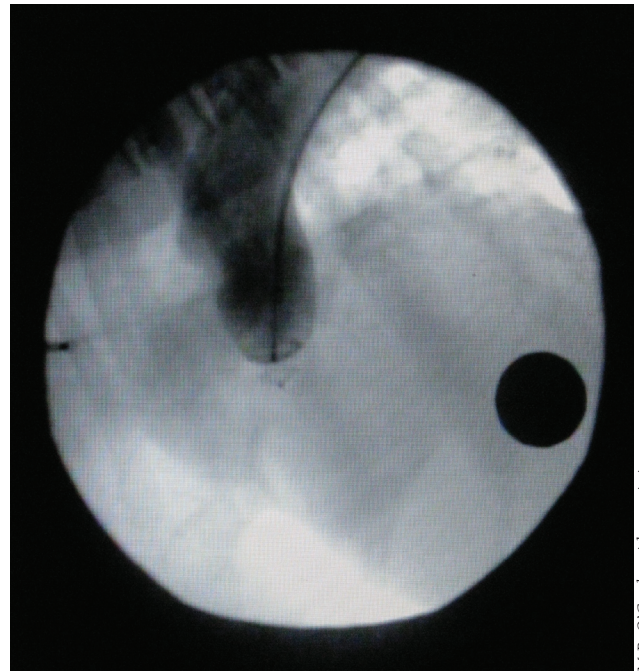


M.R. O'Grady, with permission

**Figure 4. Amplatz canine duct occluder.**

on 2 L O<sub>2</sub> and 1.5% isoflurane. Plasmalyte was administered via IV catheter at a surgical rate of 150 mL/hour. To treat bradycardia (induction HR = 50 bpm), glycopyrrolate at 0.14 mg was administered IV. During the procedure, the patient also received 2 mg hydromorphone IV and, at the end of the procedure, received 3 mg meloxicam IV.

The procedure consisted of making an incision into the left femoral artery to feed the angiographic catheter and deployment device. Angiography and transesophageal echocardiography were used to measure the diameter of the ductal opening. Then, a guiding catheter was fed through the femoral artery, into the aorta, and through the ductus arteriosus to the main pulmonary artery. The ACDO with a guide wire was fed through the catheter (Figure 5). The pulmonic side of the occluding disk was deployed in the pulmonary artery and then retracted to rest against the wall of the pulmonary artery at the opening of the ductus arteriosus. The rest of the device was then deployed within the ductus arteriosus. After testing the stability of the ductal occluder and performing a last angiogram to determine



M.R. O'Grady, with permission

**Figure 5. Angiogram showing no flow across the Amplatz canine duct occluder.**

zine at 0.6 mg postoperatively to reduce anxiety. After an uneventful night, the patient was released to the owner the next morning.

### Outcome

The patient's recovery from the procedure was unremarkable. The owner reported an increase in energy and no complications from the procedure.

At a 6-month follow up, the patient still panted excessively with exercise but showed no clinical signs of cardiac disease. Right lateral and ventrodorsal thoracic radiographs revealed the ACDO in place. Cardiac ultrasound demonstrated no flow across the ductus arteriosus and only trivial mitral and aortic valve insufficiency. M-mode measurements indicated minor reverse remodeling of the heart (left ventricle internal diameter had reduced to 5.11 cm at diastole and 4.50 cm at systole). To assist with continued reverse remodeling of the heart, the dog was continued on enalapril maleate, 0.5 mg/kg BID, which reduces the amount of circulating angiotensin II and aldosterone, both of which are profibrotic to the heart. Although PDA correction is usually accomplished at a much younger age than 5 years, Scrappy has a high probability of enjoying a normal life span. **VT**

**Acknowledgments:** The author acknowledges the support of David L. Wright, DVM, Director, Distance Learning Veterinary Technology Program, San Juan College, Farmington, NM; Michael

---

Although PDA correction is usually accomplished at a much younger age than 5 years, Scrappy has a high probability of enjoying a **normal life span**.

---

complete PDA occlusion, the guide wire was unscrewed from the device and the wire and catheter were removed from the femoral artery. The femoral artery was ligated circumferentially using 2-0 absorbable sutures. The incision was closed using 3-0 absorbable sutures in a simple continuous pattern on muscle and subcutaneous layers, and 2-0 polypropylene nonabsorbable sutures in a simple interrupted pattern on the skin.

The patient was recovered and administered aceproma-

## Glossary

- ▶ **Cardiac afterload**—the amount of pressure placed on the left ventricle as it ejects blood into the aorta.
- ▶ **Cardiac impulse**—palpable movement of the chest wall in response to heart beat.
- ▶ **Cardiac remodeling**—change in the shape and/or size of a chamber of the heart.
- ▶ **Cardiomegaly**—enlarged heart.
- ▶ **Color Doppler**—Doppler ultrasound of flow transformed by a computer into colors reflecting direction of flow of blood through a vessel or chamber.
- ▶ **Congestive heart failure**—the heart's pumping action is not sufficient to adequately perfuse body tissues.
- ▶ **Contractility**—the heart's ability to contract.
- ▶ **Ductus arteriosus**—fetal vessel that allows blood flow from the pulmonary vein to the aorta, bypassing the lungs.
- ▶ **Echocardiography**—ultrasound of the heart.
- ▶ **Hypertrophy**—enlargement of the heart muscle.
- ▶ **Mitral valve**—heart valve between the left atrium and ventricle (bicuspid valve).
- ▶ **M-mode**—time motion mode of echocardiography that is used to examine thickness and contractility.
- ▶ **Murmur**—abnormal heart sound.
- ▶ **Occlusion**—obstruction or closure of an opening.
- ▶ **Precordial thrill**—palpable vibration along the chest wall in response to heart beat.
- ▶ **Thoracotomy**—surgical incision into the thorax.
- ▶ **Transesophageal echocardiography**—echocardiography accomplished by passing the probe down the esophagus to the level of the heart.
- ▶ **Valvular insufficiency**—failure of the heart valves to close completely, allowing blood flow through the valve.
- ▶ **Vasodilatation**—dilation of the blood vessels.

R. O'Grady, DVM, MSc, Diplomate ACVIM (Cardiology), Ontario Veterinary College, Guelph, Ontario; Cameron Friesen, DVM, Friesen Veterinary Services, Edmonton, Alberta; and Samantha Crosdale, DVM, Herbers Veterinary Services, Sherwood Park, Alberta, in helping to prepare and review this case report. This report was completed as part of a course requirement for the San Juan College Distance Learning Veterinary Technology Program.

## References

1. Cornell CC, Kittleson MD, Della Torre P, et al. Allometric scaling of m-mode cardiac measurements in normal adult dogs. *J Vet Intern Med* 2004;18:311-321.
2. McKelvey D, Hollingshead KW. *Veterinary Anesthesia and Analgesia*, 3rd ed. St. Louis: Mosby; 2000.
3. Patterson DF. Epidemiologic and genetic studies of congenital heart disease in the dog. *Circ Res* 1968;23:171-202.
4. Goodwin J. Congenital heart disease. In: Miller M, Tilley L eds. *Manual of Canine and Feline Cardiology*. Philadelphia: WB Saunders; 1995:271-293.
5. Buchanan J. Patent ductus arteriosus. In: Cote E ed. *Clinical Veterinary Advisor: Dogs and Cats*. St Louis: Mosby; 2007: 820-822.
6. Buchanan JW. Patent ductus arteriosus: Morphology, pathogenesis, types and treatment. *J Vet Card* 2001;3:7-16
7. Bonagura JD. Patent ductus arteriosus. In: Tilley LP, Smith FWK Jr eds. *Blackwell's 5 Minute Veterinary Consult*, 4th ed. Hoboken: Wiley-Blackwell; 2007:1038-1039.
8. de Reeder EG, Gittenberger-de Groot AC, van Munsteren JC, et al. Distribution of prostacyclin synthase, 6-keto-prostaglandin F1 alpha, and 15-hydroxy-prostaglandin dehydrogenase in the normal and persistent ductus arteriosus of the dog. *Am J Pathol* 1989;135:881-887.
9. Brown R, Rockett A. Right-to-left shunting PDA & secondary polycythemia. *Vet Tech* 2008;29:538-543.
10. Eyster GE, Eyster JT, Cords GB, et al. Patent ductus arteriosus in the dog: Characteristics of occurrence and results of surgery in one hundred consecutive cases. *JAVMA* 1976;168:435-438.
11. Saunders AB, Miller MW, Gordon SG, Bahr A. Pulmonary embolization of vascular occlusion coils in dogs with patent ductus arteriosus. *J Vet Intern Med* 2004;18:663-666.
12. Smith PJ, Martin MWS. Transcatheter embolisation of patent ductus arteriosus using an Amplatzer vascular plug in six dogs. *Small Anim Pract* 2007;48:80-86.
13. Achen SE, Miller MW, Gordon SG, et al. Transarterial ductal occlusion with the Amplatzer vascular plug in 31 dogs. *J Vet Intern Med* 2008;22:1348-52.
14. Nguyenba TP, Tobias AH. Minimally invasive per-catheter patent ductus arteriosus occlusion in dogs using a prototype duct occluder. *J Vet Intern Med* 2008;22:129-134.



### ABOUT THE AUTHOR

**Connie K. Varnhagen, PhD, RAHT**  
Connie is a professor in Edmonton, Alberta, Canada at the University of Alberta and an animal health technologist at the General Veterinary Hospital.